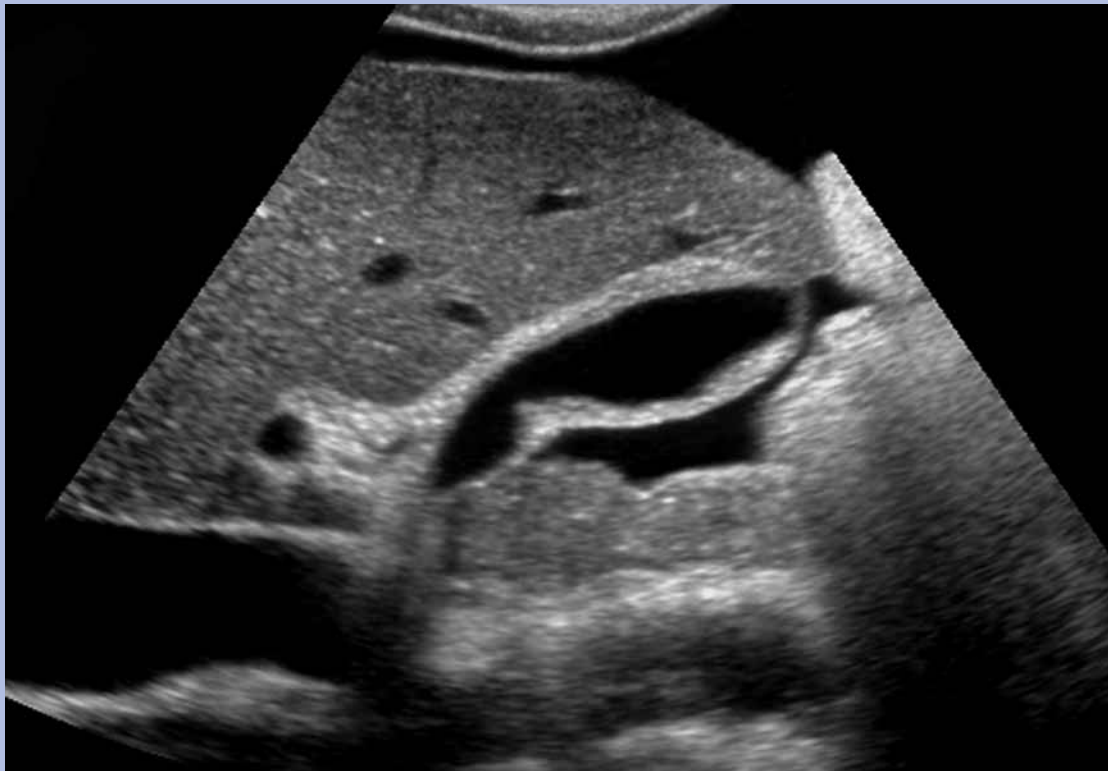


AIUM Practice Guideline for the Performance of an Ultrasound Examination of the Abdomen and/or Retroperitoneum



The association for medical ultrasound
aium
AMERICAN INSTITUTE OF ULTRASOUND IN MEDICINE

© 2008 by the American Institute of Ultrasound in Medicine

The American Institute of Ultrasound in Medicine (AIUM) is a multidisciplinary association dedicated to advancing the safe and effective use of ultrasound in medicine through professional and public education, research, development of guidelines, and accreditation. To promote this mission, the AIUM is pleased to publish, in conjunction with the American College of Radiology (ACR), this *AIUM Practice Guideline for the Performance of an Ultrasound Examination of the Abdomen and/or Retroperitoneum*. We are indebted to the many volunteers who contributed their time, knowledge, and energy to bringing this document to completion.

The AIUM represents the entire range of clinical and basic science interests in medical diagnostic ultrasound, and, with hundreds of volunteers, the AIUM has promoted the safe and effective use of ultrasound in clinical medicine for more than 50 years. This document and others like it will continue to advance this mission.

Practice guidelines of the AIUM are intended to provide the medical ultrasound community with guidelines for the performance and recording of high-quality ultrasound examinations. The guidelines reflect what the AIUM considers the minimum criteria for a complete examination in each area but are not intended to establish a legal standard of care. AIUM-accredited practices are expected to generally follow the guidelines with recognition that deviations from these guidelines will be needed in some cases, depending on patient needs and available equipment. Practices are encouraged to go beyond the guidelines to provide additional service and information as needed.



14750 Sweitzer Ln, Suite 100
Laurel, MD 20707-5906 USA
800-638-5352 • 301-498-4100
www.aium.org

I. Introduction

The clinical aspects of this guideline (Indications/Contraindications, Specifications for Individual Examinations, and Equipment Specifications) were developed collaboratively by the American Institute of Ultrasound in Medicine (AIUM) and the American College of Radiology (ACR). Recommendations for personnel requirements, written request for the examination, procedure documentation, and quality control vary between the two organizations and are addressed by each separately.

This guideline has been developed to assist practitioners performing ultrasound studies of the abdomen and/or retroperitoneum. An ultrasound examination is a proven and useful procedure for the evaluation of many structures within these anatomic areas. Depending on the clinical indications, an examination may include the entirety of the abdomen and/or retroperitoneum, a single organ, or several organs. A combination of structures may be imaged because of the location (eg, upper abdominal scan and right upper quadrant organs) or function (eg, biliary system [liver, gallbladder, and bile ducts] and both kidneys). For some patients, more focused examinations may be appropriate for evaluating specific clinical indications or to follow a known abnormality. In some cases, additional and/or specialized examinations may be necessary (eg, spectral, color, and/or power Doppler). While it is not possible to detect every abnormality using an ultrasound examination of the abdomen and/or retroperitoneum, adherence to the following guideline will maximize the probability of detecting abnormalities.

Throughout this guideline, references to Doppler evaluation may include spectral, color, or power Doppler individually or in any combination. Whenever a long-axis view is indicated, it could be either a sagittal or coronal plane.

(For pediatric considerations, see sections V.A.2, V.A.5, V.B.3, and VII.)

II. Qualifications and Responsibilities of Personnel

See the AIUM Official Statement *Training Guidelines for Physicians Who Evaluate and Interpret Diagnostic Ultrasound Examinations* and the *AIUM Standards and Guidelines for the Accreditation of Ultrasound Practices*.

III. Indications/Contraindications

Indications for an ultrasound examination of the abdomen and/or retroperitoneum include but are not limited to:

- A. Abdominal, flank, and/or back pain.
- B. Signs or symptoms that may be referred from the abdominal and/or retroperitoneal regions such as jaundice or hematuria.
- C. Palpable abnormalities such as an abdominal mass or organomegaly.
- D. Abnormal laboratory values or abnormal findings on other imaging examinations suggestive of abdominal and/or retroperitoneal pathology.
- E. Follow-up of known or suspected abnormalities in the abdomen and/or retroperitoneum.
- F. Search for metastatic disease or an occult primary neoplasm.
- G. Evaluation of suspected congenital abnormalities.
- H. Abdominal trauma.
- I. Pre- and post-transplantation evaluation.
- J. Planning and guidance for an invasive procedure.
- K. Search for the presence of free or loculated peritoneal and/or retroperitoneal fluid.

An abdominal and/or retroperitoneal ultrasound examination should be performed when there is a valid medical reason. There are no absolute contraindications.

IV. Written Request for the Examination

The written or electronic request for an ultrasound examination should provide sufficient information to allow for the appropriate performance and interpretation of the examination.

The request for the examination must be originated by a physician or other appropriately licensed health care provider or under their direction. The accompanying clinical information should be provided by a physician or other appropriate health care provider familiar with the patient's clinical situation and should be consistent with the relevant legal and local health care facility requirements.

V. Specifications for Individual Examinations

Doppler ultrasound may be useful to differentiate vascular from nonvascular structures in any location. Measurements should be considered for any abnormal area.

A. Abdomen

1. Liver

The examination of the liver should include long-axis and transverse views. The liver parenchyma should be evaluated for focal and/or diffuse abnormalities. If possible, the echogenicity of the liver should be compared with that of the right kidney. In addition, the following should be imaged:

- a. The major vessels in the region of the liver, including the inferior vena cava (IVC), the hepatic veins, the main portal vein, and, if possible, the right and left branches of the portal vein.
- b. The hepatic lobes (right, left, and caudate) and, if possible, the right hemidiaphragm and the adjacent pleural space.
- c. For vascular examinations of the native or transplanted liver, Doppler evaluation should be used to document blood flow characteristics and blood flow direction. The structures that may be examined include the hepatic arteries, hepatic veins, portal veins, the intrahepatic portion of the IVC, collateral venous pathways, and transjugular intrahepatic portosystemic shunt stents.

2. Gallbladder and Biliary Tract

The gallbladder evaluation should include long-axis and transverse views obtained in the supine position; other positions, such as left lateral decubitus, erect, and prone positions, may be necessary to evaluate the gallbladder and its surrounding area completely, particularly when stones and/or sludge are observed. Measurements may aid in determining gallbladder wall thickening. If the patient presents with pain, tenderness to transducer compression should be assessed.

The intrahepatic ducts can be evaluated by obtaining views of the liver demonstrating the right and left branches of the portal vein. Doppler imaging may be used to differentiate hepatic arteries and portal veins from bile ducts. The intrahepatic and extrahepatic bile ducts should be evaluated for dilatation, wall thickening, intraluminal findings, and other abnormalities. The size of the bile duct in the porta hepatis should be

documented. When visualized, the distal common bile duct in the pancreatic head should be evaluated.

A routine gallbladder examination should be conducted on an adequately distended gallbladder. In most cases, fasting for 8 hours before the examination will permit adequate distension of a normally functioning gallbladder in adults and children. In infants and some adults, adequate distention may be achieved in less time.

3. Pancreas

Whenever possible, all portions of the pancreas—head, uncinate process, body, and tail—should be identified. Orally administered water or a contrast agent may afford better visualization of the pancreas. The following should be assessed in the examination of the pancreas:

- a. Parenchymal abnormalities.
- b. The distal common bile duct in the region of the pancreatic head.
- c. The pancreatic duct for dilatation and any other abnormalities, with dilatation confirmed by measurement.
- d. The peripancreatic region for adenopathy and/or fluid.

4. Spleen

Representative views of the spleen in long-axis and transverse projections should be obtained. Doppler imaging may be used to determine the presence and direction of flow in the splenic vein and artery. Splenic measurement may be helpful in assessing enlargement. Echogenicity of the left kidney should be compared to splenic echogenicity when possible. An attempt should be made to demonstrate the left hemidiaphragm and the adjacent pleural space.

5. Bowel

The bowel may be evaluated for wall thickening, dilatation, muscular hypertrophy, masses, and other abnormalities. Sonography of the pylorus and surrounding structures may be indicated in the evaluation of the vomiting infant. Compression sonography may be necessary to visualize the appendix or other bowel loops. Measurements may aid in determining bowel wall thickening. Color Doppler imaging may be done to assess blood flow.

6. Peritoneal Fluid

Evaluation for free or loculated peritoneal fluid should include documentation of the extent and location of any fluid identified.

For evaluating peritoneal spaces for bleeding after traumatic injury, particularly blunt trauma, the examination known as focused abdominal sonography for trauma (or focused assessment with sonography for trauma) may be performed.

The objective of the abdominal portion of the examination is to analyze the abdomen for free fluid. Longitudinal and transverse plane images should be obtained in the right upper quadrant through the area of the liver with attention to fluid collections peripheral to the liver and in the subhepatic space. Longitudinal and transverse plane images should be obtained in the left upper quadrant through the area of the spleen, with attention to fluid collections peripheral to the spleen. Longitudinal and transverse images should be obtained at the periphery of the left and right abdomen in the areas of the left and right paracolic gutters for evidence of free fluid. Longitudinal and transverse midline images of the pelvis are obtained to evaluate for free pelvic fluid. Analysis through a fluid-filled bladder (which if necessary can be filled through a Foley catheter when possible) may help in the evaluation of the pelvis.

7. Abdominal Wall

The examination should include images of the abdominal wall in the location of symptoms or signs. The relationship of any identified mass to the peritoneum should be demonstrated. Any defect in the peritoneum and abdominal wall musculature should be documented. The presence or absence of bowel, fluid, or other tissue contained within any abdominal wall defect should be noted. Images obtained in the upright position and/or with use of the Valsalva maneuver may be helpful. A Doppler examination may be useful to define the relationship of blood vessels to a detected mass.

B. Retroperitoneum

1. Kidneys

The examination should include long-axis and transverse views of the upper poles, midportions, and lower poles of the kidneys. The cortex and renal pelvises should be assessed. A maximum measurement of renal length should be recorded for both kidneys. Decubitus, prone, or upright positioning may provide better images of the kidneys. When possible, renal echogenicity should be compared to echogenicity of the adjacent liver or spleen. The kidneys and perirenal regions should be assessed for abnormalities.

For vascular examination of the kidneys, Doppler imaging can be used:

- a. To assess renal arterial and venous patency.
- b. To evaluate adults suspected of having renal artery stenosis. For this application, angle-adjusted measurements of the peak systolic velocity should be made proximally, centrally, and distally in the extrarenal portion of the main renal arteries when possible. The peak systolic velocity of the adjacent aorta (or iliac artery in transplanted kidneys) should also be documented for calculating the ratio of renal to aortic peak systolic velocity. Spectral Doppler evaluation of the intrarenal arteries from the upper and lower portions of the kidneys, obtained to evaluate the early systolic peak, may be of value as indirect evidence of proximal stenosis in the main renal artery.

2. Urinary Bladder and Adjacent Structures

When performing a complete ultrasound evaluation of the urinary tract, transverse and longitudinal images of the distended urinary bladder and its wall should be included, if possible. Bladder lumen or wall abnormalities should be noted. Dilatation or other distal ureteral abnormalities should be documented. Transverse and longitudinal scans may be used to demonstrate any postvoid residual, which may be quantitated and reported.

3. Adrenal Glands

When possible, usually in the neonate or young infant, long-axis and transverse images of the adrenal glands may be obtained. The adrenal glands are infrequently seen in adults. When visualized, the size of the gland should be documented, as well as the presence of hemorrhage, masses, or other abnormalities.

4. Aorta

Representative images of the aorta in longitudinal and transverse planes should be obtained as appropriate. When evaluation of the aorta is specifically requested, see the *AIUM Practice Guideline for the Performance of Diagnostic and Screening Ultrasound Examinations of the Abdominal Aorta*.

5. Inferior Vena Cava

Transverse and longitudinal images of the IVC should be obtained. Patency and abnormalities may be evaluated with Doppler imaging. Vena cava filters, interruption devices, or catheters may need to be localized with respect to the hepatic and/or renal veins.

VI. Documentation

Adequate documentation is essential for high-quality patient care. There should be a permanent record of the ultrasound examination and its interpretation. Images of all appropriate areas, both normal and abnormal, should be recorded. Variations from normal size should be accompanied by measurements. Images should be labeled with the patient identification, facility identification, examination date, and side (right or left) of the anatomic site imaged. An official interpretation (final report) of the ultrasound findings should be included in the patient's medical record. Retention of the ultrasound examination should be consistent both with clinical needs and with relevant legal and local health care facility requirements.

Reporting should be in accordance with the *AIUM Practice Guideline for Documentation of an Ultrasound Examination*.

VII. Equipment Specifications

Abdomen and/or retroperitoneum ultrasound studies should be conducted with real-time scanners, preferably using sector or linear (straight or curved) transducers. The equipment should be adjusted to operate at the highest clinically appropriate frequency, realizing that there is a trade-off between resolution and beam penetration. For most preadolescent pediatric patients, mean frequencies of 5 MHz or greater are preferred, and in neonates and small infants, a higher-frequency transducer is often necessary. For adults, mean frequencies between 2 and 5 MHz are most commonly used. When Doppler studies are performed, the Doppler frequency may differ from the imaging frequency. Diagnostic information should be optimized while keeping total ultrasound exposure as low as reasonably achievable.

VIII. Quality Control and Improvement, Safety, Infection Control, and Patient Education Concerns

Policies and procedures related to quality control, patient education, infection control, and safety should be developed and implemented in accordance with the *AIUM Standards and Guidelines for the Accreditation of Ultrasound Practices*.

Equipment performance monitoring should be in accordance with the *AIUM Standards and Guidelines for the Accreditation of Ultrasound Practices*.

Acknowledgments

This guideline was developed by the American Institute of Ultrasound in Medicine (AIUM) in collaboration with the American College of Radiology (ACR), according to the process described in the *AIUM Clinical Standards Committee Manual*.

Principal Revisers

Harris L. Cohen, MD
John P. McGahan, MD

Collaborative Subcommittees

AIUM

Barbara S. Hertzberg, MD
Jon W. Meilstrup, MD
Laurence Needleman, MD

ACR

Beverly E. Hashimoto, MD, *Chair*
W. Dennis Foley, MD
Ronald R. Townsend, MD

AIUM Clinical Standards Committee

Mary Frates, MD, *Chair*
Bryann Bromley, MD, *Vice Chair*
Teresita Angtuaco, MD
Marie De Lange, BS, RDMS, RDCS, RT
Brian Garra, MD
Barbara Hertzberg, MD
Stephen Hoffenberg, MD
Richard Jaffe, MD
Alfred Kurtz, MD
Joan Mastrobattista, MD
John McGahan, MD
Jon Meilstrup, MD
William Middleton, MD
Thomas Nelson, PhD
David Paushter, MD
Cindy Rapp, BS, RDMS
Michelle Robbin, MD
Henrietta Kotlus Rosenberg, MD
Eugene Toy, MD
Lami Yeo, MD

Comments Reconciliation Committee

Julie K. Timins, MD, *Cochair*

Bill H. Warren, MD, *Cochair*

Albert L. Blumberg, MD

Harris L. Cohen, MD

Mary C. Frates, MD

Gretchen A. Gooding, MD

Beverly E. Hashimoto, MD

David C. Kushner, MD

Paul A. Larson, MD

Lawrence A. Liebscher, MD

Beatrice L. Madrazo, MD

John P. McGahan, MD

Jon W. Meilstrup, MD

Matthew S. Pollack, MD

Carol M. Rumack, MD

References

1. Babcock DS, Patriquin HB. The pediatric kidney and adrenal glands. In: Rumack CM, Wilson SR, Charboneau JW, et al (eds). *Diagnostic Ultrasound*. 3rd ed. Philadelphia, PA: Elsevier Mosby; 2005:1905–1940.
2. Baxter GM. Imaging in renal transplantation. *Ultrasound Q* 2003; 19:123–138.
3. Desser TS, Sze DY, Jeffrey RB. Imaging and intervention in the hepatic veins. *AJR Am J Roentgenol* 2003; 180: 1583–1591.
4. Gandolfi L, Torresan F, Solmi L, Pucetti A. The role of ultrasound in biliary and pancreatic diseases. *Eur J Ultrasound* 2003; 16:141–159.
5. Guimaraes CM, Correia MM, Baldisserott M, de Queiroz Aires EP, Coelho JF. Intraoperative ultrasonography of the liver in patients with abdominal tumors: a new approach. *J Ultrasound Med* 2004; 23:1549–1555.
6. Hagen-Ansert SL. Introduction to abdominal scanning techniques and protocols. In: Hagen-Ansert SL (ed). *Textbook of Diagnostic Ultrasonography*. 5th ed. St Louis, MO: CV Mosby Co; 2001:42–69.
7. Hagen-Ansert SL. The spleen. In: Hagen-Ansert SL (ed). *Textbook of Diagnostic Ultrasonography*. 5th ed. St Louis, MO: CV Mosby Co; 2001:308–326.
8. Ho LM, Thomas J, Fine SA, Paulson EK. Usefulness of sonographic guidance during percutaneous biopsy of mesenteric masses. *AJR Am J Roentgenol* 2003; 180:1563–1566.
9. Jeffrey RB. Right lower-quadrant pain: rule out appendicitis. In: Bluth EI, Arger PH, Benson CB, et al (eds). *Ultrasound: A Practical Approach to Clinical Problems*. New York, NY: Thieme; 2000:125–132.
10. Kim NR, Kim SH, Lee JM, et al. Sonographic features of an intraductal polypoid mass: differentiation between hepatocellular carcinoma and intraductal cholangiocarcinoma. *J Ultrasound Med* 2004; 23:1283–1291.
11. Kitamura H, Kobayashi C. Impairment of change in diameter of the hepatic portion of the inferior vena cava: a sonographic sign of liver fibrosis or cirrhosis. *J Ultrasound Med* 2005; 24:355–359.
12. Kimura A, Otsuka T. Emergency center ultrasonography in the evaluation of hemoperitoneum: a prospective study. *J Trauma* 1991; 31:20–23.
13. Koito K, Namieno T, Nagakawa T, et al. Pancreas: imaging diagnosis with color/power Doppler ultrasonography, endoscopic ultrasonography, and intraductal ultrasonography. *Eur J Radiol* 2001; 38:94–104.
14. Laing FC. Jaundice. In: Bluth EI, Arger PH, Benson CB, et al (eds). *Ultrasound: A Practical Approach to Clinical Problems*. New York, NY: Thieme; 2000:17–29.
15. Lingawi SS, Buckley AR. Focused abdominal US in patients with trauma. *Radiology* 2000; 217:426–429.
16. McGahan J, Richard J, Fogata M. Emergency ultrasound in trauma patients. *Radiol Clin North Am* 2004; 42:417–425.
17. McGahan JP, Rose J, Coates TL, Wisner DH, Newberry P. Use of ultrasonography in the patient with acute abdominal trauma. *J Ultrasound Med* 1997; 16:653–662.
18. Middleton WD. Right upper quadrant pain. In: Bluth EI, Arger PH, Benson CB, et al (eds). *Ultrasound: A Practical Approach to Clinical Problems*. New York, NY: Thieme; 2000:3–16.
19. Middleton WD, Kurtz AB, Hertzberg BS. Kidney. In: *Ultrasound: The Requisites*. 2nd ed. St Louis, MO: CV Mosby Co; 2004:103–151.
20. Muradali D, Wilson SR. Organ transplantation. In: Rumack CM, Wilson SR, Charboneau JW, et al (eds) *Diagnostic Ultrasound*. 3rd ed. Philadelphia, PA: Elsevier Mosby; 2005:675–704.
21. Radermacher J, Chavan J, Bleck J, et al. Use of Doppler ultrasonography to predict the outcome of therapy for renal artery stenosis. *N Engl J Med* 2001; 344:410–417.
22. Ralls PW. Hyperamylasemia. In: Bluth EI, Arger PH, Benson CB, et al (eds). *Ultrasound: A Practical Approach to Clinical Problems*. New York, NY: Thieme; 2000:67–75.
23. Ralls PW. Ultrasound to assess respectability of periampullary neoplasms. In: Bluth EI, Arger PH, Benson CB, et al (eds). *Ultrasound: A Practical Approach to Clinical Problems*. New York, NY: Thieme; 2000:58–66.
24. Robbin ML, van Leeuwen DJ. Sonography in the evaluation of abnormal liver tests. In: Bluth EI, Arger PH, Benson CB, et al (eds). *Ultrasound: A Practical Approach to Clinical Problems*. New York, NY: Thieme; 2000:30–45.

25. Scott T. Sonographic detection of the normal appendix: does the combination of real-time spatial compounding and tissue harmonic imaging make a difference? *J Diagn Med Sonogr* 2004; 5:326–334.
26. Siegel MJ. Liver. In: Siegel MJ (ed). *Pediatric Sonography*. 3rd ed. Philadelphia, PA: Lippincott Williams & Wilkins; 2001: 213–273.
27. Siegel MJ. Gallbladder and biliary tract. In: Siegel MJ (ed). *Pediatric Sonography*. 3rd ed. Philadelphia, PA: Lippincott Williams & Wilkins; 2001:275–303.
28. Siegel MJ. Urinary tract. In: Siegel MJ (ed). *Pediatric Sonography*. 3rd ed. Philadelphia, PA: Lippincott Williams & Wilkins; 2001:385–473.
29. Sivit C, Siegel MJ. Gastrointestinal tract. In: Siegel MJ (ed). *Pediatric Sonography*. 3rd ed. Philadelphia, PA: Lippincott Williams & Wilkins; 2001:337–383.
30. Sivit C, Siegel MJ. Spleen and peritoneal cavity. In: Siegel MJ (ed). *Pediatric Sonography*. 3rd ed. Philadelphia, PA: Lippincott Williams & Wilkins; 2001:305–336.
31. Sofka CM. Multicentre aneurysm screening study (MASS): cost effectiveness analysis of screening for abdominal aortic aneurysms based on four-year results from a randomized controlled trial. *Ultrasound Q* 2003; 19:106–107.
32. Soudack M, Epelman M, Maor R, et al. Experience with focused abdominal sonography for trauma (FAST) in 313 pediatric patients. *J Clin Ultrasound* 2004; 32:53–61.
33. Thurston W, Wilson SR. The urinary tract. In: Rumack CM, Wilson SR, Charboneau JW, et al (eds). *Diagnostic Ultrasound*. 3rd ed. Philadelphia, PA: Elsevier Mosby; 2005:321–394.